

## Surgical treatment of an isolated left jugular vein aneurysm: a case report

İhsan Alur, Serkan Girgin, Bilgin Emrecan, Ali Vefa Özcan

Received: March 09, 2014 Accepted: March 31, 2014

Jugular venous aneurysms are rare causes of neck masses which occur during straining or Valsalva maneuver and most frequently seen in children. Symptoms include painless and enlarging mass with conditions which increase intrathoracic pressure such as coughing, straining or Valsalva maneuver. Although the exact etiology has not been fully elucidated, congenital defect in the muscular layer, compression of apex of right lung or clavicle to the jugular vein, mechanical obstruction of the lower part of the neck or upper mediastinum, insufficient compliance of vein, thoracic outlet syndrome or compression of anterior scalene muscle may play a role. Jugular vein aneurysms can be treated surgically; however, timing of the surgery is controversial. Linear plication and encapsulation are the most commonly performed surgeries. Herein, we present a seven-year-old boy with left internal jugular vein aneurysm who underwent a successful surgical repair.

Keywords: Aneurysm; child; jugular vein; surgery.

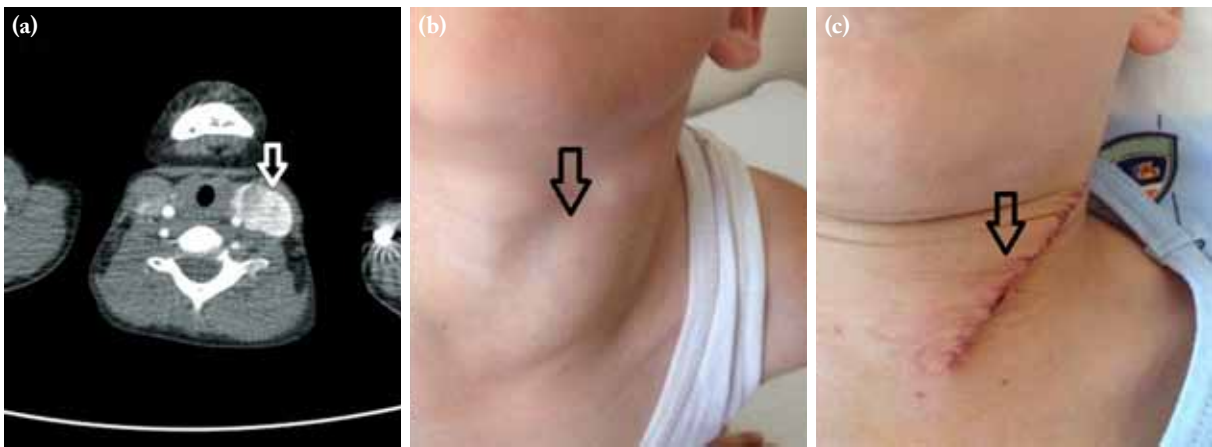
Jugular vein aneurysm (JVA) is described as a fusiform or saccular dilatation of the jugular vein without torsion in the jugular vein wall.<sup>[1]</sup> The etiology of JVA is unclear, however some predisposing factors have been suggested such as congenital agenesis of the muscular layer of the vein wall, external compression of the jugular vein by the cupola of the right lung and head of the clavicle, mechanical obstruction of the inferior neck and upper mediastinum, the inflexibility of the vein wall, thoracic outlet syndrome and anterior scalen compression.<sup>[1]</sup> On histologic examination, there can be loss of elastic fiber and intimal hyalinization or the wall of the vein can be totally normal.<sup>[2]</sup> It is generally seen in children with the right jugular vein being affected most and is two times more common in males.<sup>[3]</sup> In addition, JVA can be considered as an asymptomatic and benign state, however, in some cases, there can be complaints such as shortness of breath, feeling of suffocation or weight on the chest, tongue pain, discomfort during physical exercise, and may also cause cosmetic-psychological complaints. In the differential diagnosis, laryngocele growing (swelling) with Valsalva on the neck, cystic hygroma, external laryngeal diverticula, upper mediastina cyst or tumor and other vascular pathologies should be also considered.<sup>[4]</sup> The diagnosis is based on the evaluation through Doppler ultrasound (USG) or contrast computed tomography (CT). Doppler USG codes the turbulent flow created during Valsalva, while CT demonstrates the deep anatomical structures adjacent to the jugular vein.<sup>[5]</sup>

### CASE REPORT

A seven-year-old boy applied with the complaint of a swelling on the left side of his neck which grew larger with crying or blowing into balloons for the past one year. On physical examination, a non-pulsating compressible mass of soft character was palpated on the left side of the neck (Figure 1b). The hyperelastic skin and hyperextensible joints were suggestive of Ehlers-Danlos syndrome; however, medical genetic consultation findings were normal. There was no history of trauma or infection of the neck and upper thorax. On ultrasonography, a mass on the jugular vein measuring 15x12 mm before Valsalva and 38x24 mm after Valsalva was noted. Turbulent flow through the vein lumen with a thin movable valve was prominent. This appearance was primarily interpreted as an enlargement of the jugular vein with Valsalva secondary to valve damage. There was no significant cystic-solid sonopathology. On CT angiogram, it was seen that the left jugular vein was approximately 27 mm in diameter at a level of 1 cm above where it drained into the subclavian vein (Figure 1a). An incision appropriate to the line of the left carotid artery was performed under general anesthesia. The internal jugular vein aneurysm (IJVA) was exposed (Figure 2a).

Department of Cardiovascular Surgery, Medical Faculty of Pamukkale University, Denizli, Turkey

**Corresponding author:** İhsan Alur, M.D. Pamukkale Üniversitesi Tıp Fakültesi Kalp ve Damar Cerrahisi Anabilim Dalı, 20070 Kınıklı, Denizli, Turkey.  
Tel: +90 532 - 392 60 78 e-mail: alur\_i@hotmail.com



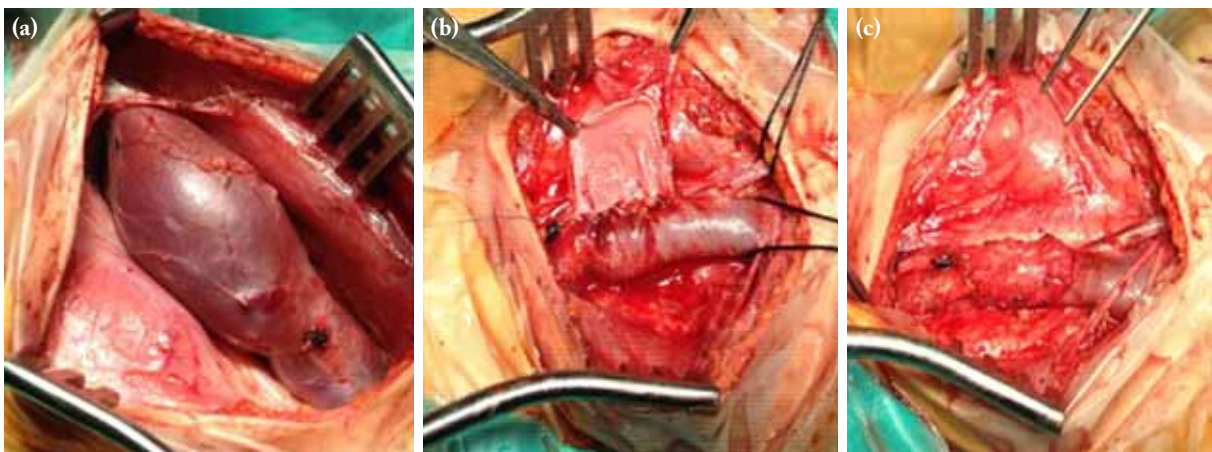
**Figure 1.** (a) Contrast-enhanced computed tomography image preoperatively, (b) preoperative view of aneurysm, (c) postoperative view of incision.

A segmental dilatation with a diameter of 3 cm was observed on the IJVA. The external jugular vein was normal. The aneurysmal segment was clamped using side clamps. Linear plication was performed with 6/0 prolene suture (Figure 2b). The aneurysmal sac was opened longitudinally and sutured like a flap to the anterior wall of the IJV to strengthen the anterior wall (Figure 2c). The patient was discharged without any problems at the fifth postoperative day (Figure 1c).

## DISCUSSION

The surgical treatment indications for JVA are still controversial. Some authors recommend a conservative approach, while others perform surgery after diagnosis. This benign congenital venous abnormality may cause some complications.<sup>[6,7]</sup> The

vein wall becomes thinner and weaker secondary to aneurysmal expansion, thereby leading to rupture and bleeding. Since the ability and awareness of self-protection against external traumas are weaker in children than in adults, there is the risk of rupture in these cases. An untreated JVA may cause bleeding during surgical procedures such as tonsillectomy.<sup>[8]</sup> Turbulent flow which develops due to the hemodynamic changes occurring in dilated veins may also cause thrombophlebitis, intramural thrombus, pulmonary embolism, and congestive heart failure.<sup>[9]</sup> A long-term follow-up has shown that dilatations of the jugular vein continue to grow.<sup>[1,4]</sup> We also need to remember the cosmetic-psychological component. This kind of abnormality is likely to affect the development of personality and inner peace psychosocially.



**Figure 2.** (a) Operative view of jugular venous aneurysm, (b) linear plication view, (c) the end view of jugular vein.

Treatment of JVA is surgical. Ligation or resection is performed, if the dilated segment is located in the external jugular vein. However, care is required with unilateral or bilateral dilatation of the internal jugular vein (IJV), because the IJV provides about 70% of the venous drainage for the brain.<sup>[6]</sup> On the other hand, ligation or resection can cause fatal complications. Jianhong et al.<sup>[6]</sup> reported vomiting due to an increased intracranial pressure, headache, unilateral edema of the neck and craniofacial region after IJV ligation and right pontine lacunar infarction on MR imaging in three of the 51 patients operated. They recommended a vein repair + encapsulation by longitudinal suturing technique instead of ligation and resection for unilateral or bilateral IJVA cases and reported that it was safer.

We applied vein repair + encapsulation by longitudinal suture technique (linear plication) in our case after placing a side clamp on the dilated segment of the IJV. After placing the side clamp, we performed a longitudinal incision along the dilated segment of the jugular vein and wrapped the encapsulation circumferentially to the jugular vein using linear suturing. We believe that this technique strengthens the vascular wall, preventing recurrences. With side clamp repair, we also protected the brain hemodynamics and did not increase the intracranial pressure. Strengthening the vascular wall with the encapsulation technique can be performed using Dacron or PTFE patches.<sup>[6]</sup> We think that our method (plication + encapsulation) is superior to using synthetic grafts in growing children.

Furthermore, an endoscopic repair case as an alternative to open surgery has been reported in the literature.<sup>[10]</sup> Although the duration of the procedure is longer and postoperative pain is more, the pathology can be improved without neck scars with the endoscopic method.

In conclusion, JVA is a rare benign venous pathology in children. It can cause severe complications, if left

untreated. Also, it can adversely affect the psychosocial personality development of the child. We successfully performed the plication and encapsulation in surgical treatment of JVA. We think that our method is more advantageous than using synthetic grafts in growing children.

### Declaration of conflicting interests

The authors declared no conflicts of interest with respect to the authorship and/or publication of this article.

### Funding

The authors received no financial support for the research and/or authorship of this article.

---

## REFERENCES

1. Paleri V, Gopalakrishnan S. Jugular phlebectasia: theory of pathogenesis and review of literature. *Int J Pediatr Otorhinolaryngol* 2001;57:155-9.
2. Ekim H, Ozen S. Primary venous aneurysm of the external jugular vein. *Eastern J Med* 2002;7:24-5.
3. Available from: <https://www.home.coqui.net/titolugo/PSU17201> [Accessed November 01, 2014]
4. Ogbole GI, Irabor AE, Adeoye PO, Yusuf BP. Internal jugular phlebectasia in an African adult. *BMJ Case Rep* 2010;2010.
5. Bora MK. Internal Jugular Phlebectasia: Diagnosis by Ultrasonography, Doppler and Contrast CT. *J Clin Diagn Res* 2013;7:1194-6.
6. Jianhong L, Xuewu J, Tingze H. Surgical treatment of jugular vein phlebectasia in children. *Am J Surg* 2006;192:286-90.
7. Sander S, Eliçevik M, Unal M, Vural O. Jugular phlebectasia in children: is it rare or ignored? *J Pediatr Surg* 1999;34:1829-32.
8. Burstin PP, Hooper RE. Massive primary hemorrhage during tonsillectomy from a large venous varicosity. *Otolaryngol Head Neck Surg* 1997;117:287-90.
9. Swami SLH, Nambiar S. Focal ectasia of internal jugular vein. *Med J Armed Forces India* 2009;65:282-3.
10. Chang YT, Lee JY, Wang JY, Chiou CS. Transaxillary subfascial endoscopic approach for internal jugular phlebectasia in a child. *Head Neck* 2010;32:806-11.