



## Atypical Presentation a Case of COVID-19: Bilateral Deep Vein Thrombosis and Pseudoparalysis in a Young Woman

İhsan Alur<sup>1</sup> and Erkam Kömürçü<sup>2\*</sup>

<sup>1</sup>Department of Cardiovascular Surgery, Istinye University G.O.P Medical Park Hospital, Turkey

<sup>2</sup>Department of Orthopedics and Traumatology, Istinye University G.O.P Medical Park Hospital, Turkey

### Abstract

Coronavirus pandemic is a viral infection that affects the world and has high mortality and infectiousness. The most common symptoms of this infection are fever, cough and shortness of breath. In addition, there may be atypical symptoms such as muscle pain and weakness. COVID-19 should also be considered in cases with other systemic manifestations without lung and upper respiratory tract involvement. In this article, we wanted to share a twenty-eight-year-old female patient presenting with bilateral deep vein thrombosis and pseudoparalysis.

**Keywords:** Deep vein thrombosis; Pseudoparalysis; COVID-19

### Introduction

COVID-19 is a highly infectious viral infection that broke out in Wuhan, Hubei Province in the People's Republic of China in December 2019. The most common symptoms of this infection are fever (98%), cough (76%), and shortness of breath (55%). In addition, there may be atypical symptoms such as muscle pain (44%), malaise (44%) [1]. In some patients, upper respiratory tract involvement may be in the precedence and may occur with a flu-like clinic. Other findings include an increase in sputum secretion, headache, diarrhea, and rare nose bleeding [1]. The average age of occurrence is reported between 49 and 55 [1,2]. The average time from the onset of symptoms to hospitalization for the first time is seven days [1]. The average time between the onset of symptoms and the first time of hospitalization is seven days [1]. As stated in a review, approximately 73% of patients are male and 27% are female, 32% have co-morbid diseases such as diabetes, hypertension, and other cardiovascular diseases, and 32% of patients also have intensive care and respiratory support needs [1]. The most serious complication of this disease is acute respiratory failure and death [1,2]. In the literature, the mortality rate due to COVID-19 is reported to be 11% on average [1]. COVID-19 should also be considered in cases with other systemic manifestations without lung and upper respiratory tract involvement.

In this paper, we wanted to share an interesting case presented with bilateral deep vein thrombosis and pseudoparalysis.

### Case Presentation

A twenty-eight-year-old female patient was admitted to the orthopedics and rheumatology outpatient clinic with severe leg pain that started suddenly 2 days ago. In the anamnesis of the patient, it was determined that she had undergone bichectomy and rhinoplasty 4 weeks ago, and had undergone left-sided peripheral facial paralysis after this operation. Therefore, it was stated that corticosteroid (prednisolone) treatment was started. One week after the operation, she was admitted to the hospital for fever and weakness, and her routine examinations (thorax CT, rapid COVID-19 antibody test, hemogram, etc.) were reported to be normal. The patient did not have any important features except smoking. In the physical examination of the patient, breathing sounds were normal, both lungs were ventilated equally. No additional sound or murmur was heard during heart auscultation. The blood pressure value was 90/60 mmHg. All peripheral pulses were palpable. The Range of Motion (ROM) of the knee joint was within normal limits. In the bilateral popliteal regions and the medial joint space, there was tenderness in palpation in the distal femoral condyle. There were no additional pathological findings. There was a minimal complicated Baker cyst in the posterior of the left knee in bilateral knee Magnetic Resonance (MR) imaging due to the suspicion of an aseptic necrosis due to steroid use (Figure 1a, 1b). The patient a written informed consent was obtained. Due to the persistence of severe leg pain, bilateral lower extremity venous

### OPEN ACCESS

#### \*Correspondence:

Erkam Kömürçü, Department of Orthopedics and Traumatology, Istinye University G.O.P Medical Park Hospital, Bursa, Turkey,  
E-mail: erkakom@yahoo.com

Received Date: 10 Mar 2021

Accepted Date: 30 Mar 2021

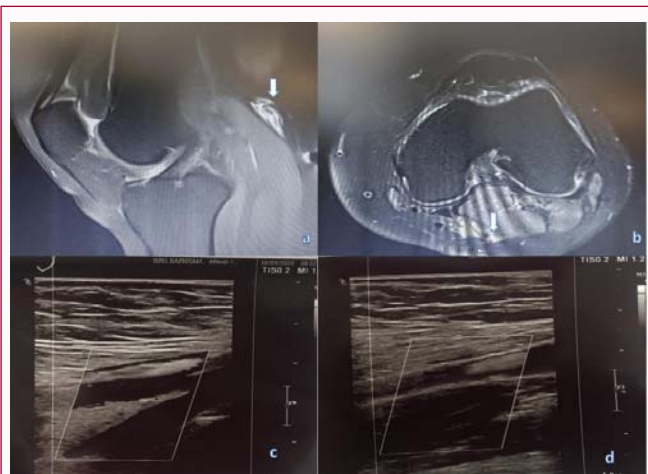
Published Date: 02 Apr 2021

#### Citation:

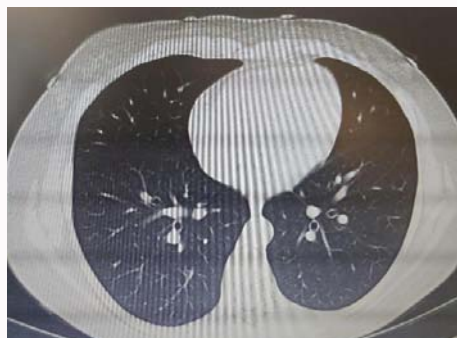Alur İ, Kömürçü E. Atypical Presentation a Case of COVID-19: Bilateral Deep Vein Thrombosis and Pseudoparalysis in a Young Woman. *Ann Arthritis Clin Rheumatol.* 2021; 4(1): 1022.

Copyright © 2021 Erkam Kömürçü.

This is an open access article distributed under the Creative Commons Attribution License, which permits unrestricted use, distribution, and reproduction in any medium, provided the original work is properly cited.



**Figure 1:** a) MR image of the knee in the sagittal section (white arrow shows Baker cyst) b) Knee MR image in transverse section (white arrow shows Baker cyst) c) Venous Doppler USG image of popliteal vein thrombosis d) Venous Doppler USG image of popliteal vein thrombosis.



**Figure 2:** Thorax CT image in transverse section.

Doppler performed with the suspicion of vascular pathology was reported that both popliteal veins were thrombosed until trifurcation and other arterial and venous structures were normal (Figure 1c, 1d). The patient was started on anticoagulant therapy and limb elevation. Electromyography (EMG) was performed after the patient continued severe bilateral leg pain despite analgesic treatment. EMG was reported as normal. Because of the coronavirus pandemic, the patient's nose swab was taken on the possibility of having COVID-19 infection and the Polymerase Chain Reaction (PCR) test was positive. The patient's C-Reactive Protein (CRP), lymphocyte count, ferritin and D-dimer values were within normal ranges. Thorax CT imaging of the patient was also normal (Figure 2). The patient received antiviral treatment Favipiravir, Hydroxychloroquine and other supportive medications for five days. The patient's complaints of knee and leg pain and pseudoparalysis disappeared. The patient was discharged after being treated.

## Discussion

Severe Acute Respiratory Syndrome Coronavirus 2 (SARS-CoV-2) was named COVID-19 disease by the World Health Organization (WHO) and was considered a global health emergency [3]. It is known that human respiratory system cells are targets in primary pathogenesis of coronavirus [3]. The most important reasons for COVID-19 patients coming to hospital are bilateral widespread lung infiltrations in imaging methods with dry cough, fever, dyspnea and malaise. Although the main involvement in COVID-19 is

the respiratory system, more than one mechanism is involved in mortality. One of these mechanisms is coagulopathy and it's induced Disseminated Intravascular Coagulation (DIC). Coagulation disorder seen in patients makes COVID-19 treatment more difficult and increases the mortality rates associated with it. COVID-19 infection progresses with normal Prothrombin Time (PT) activated partial thromboplastin time (a PTT) and thrombocyte count, with an increase in D-dimer and fibrinogen values [3].

In addition to these symptoms, gastrointestinal symptoms such as headache, chest pain, chills and pharyngeal pain, diarrhea, nausea and vomiting may also be seen [3]. Our case differently was admitted to the hospital with bilateral severe knee pain and bilateral deep vein thrombosis. To our knowledge, there is no report of bilateral distal deep vein thrombosis without pulmonary symptoms with COVID-19 in the literature. In most patients with COVID-19, in addition to respiratory symptoms and respiratory imaging findings, absolute leukocyte, neutrophil and lymphocyte count decrease as laboratory findings, while C-Reactive Protein (CRP) and ferritin increase considerably, procalcitonin generally remains within normal limits [3]. However, in our case, leukocyte, neutrophil and lymphocyte ratio, CRP and procalcitonin were normal. COVID-19 IgM and IgG rapid antibody test was seen as negative in our case. These differences can be interpreted for the patient to have the disease with relatively mild symptoms. In a recent case reported by the Zhoushan Health Commission, they reported that the patient's contact with COVID-19 infected patients had no obvious respiratory symptoms and typical CT findings; in addition, virus RNA was negative in the pharyngeal test but positive in stool samples [4]. In patients with diarrhea and gastrointestinal symptoms accompanying atypical pulmonary findings, the negative test in the pharyngeal swab samples and negative in our case before limb pain can be interpreted as a similar situation. Zhu et al. [4] published the symptoms observed in these patients in the meta-analysis in which they collected disease symptoms in patient groups followed by the diagnosis of 3,602 COVID-19. When the symptoms mentioned in this publication are examined, there are no patients present in our patient. Besides typical pulmonary complaints, cases with testicular, abdominal pain and diarrhea, characterized by atypical symptoms have also been reported [3,5]. Unlike the cases reported in the literature in our case, despite the absence of pulmonary symptoms and laboratory findings, the patient had bilateral knee pain and bilateral distal deep vein thrombosis to cause pseudo paralysis. In our case, smoking and corticosteroid use history was only positive as a risk factor. Studies have reported that active smoking is an independent risk factor for VTE in middle-aged men and women. The effect of smoking on VTE appears to be more acute and dose dependent. The use of cigarettes and other tobacco products reduces fibrinolysis with procoagulant effect and increases inflammation and blood viscosity [6]. Active smoking has also been associated with increased Factor VIII and plasma fibrinogen levels, which are risk factors for VTE [7]. Since our patient was young, her protein S activity was low in thrombophilia screening, suggesting that COVID-19 might have triggered venous thrombosis. In severe systemic diseases, dysfunction of endothelial cells induced by infection leads to hypercoagulopathy with increased thrombin production and loss of fibrinolysis [8]. COVID-19 has been reported to cause widespread venous thromboembolism and disseminated intravascular coagulation caused by coagulopathy, especially in older patients [8]. In addition, cases of deep vein thrombosis leading to pulmonary artery embolism have been reported in the literature

[7,8]. Cui et al. [7] declared that venous thromboembolism increases in patients with severe corona virus pneumonia and this increases mortality. Increased inflammatory cytokines and its activation to coagulopathy seem to increase venous thromboembolism. It has been suggested that coagulopathy increases and thrombotic complications occur as a result of increased immune response in patients with severe COVID-19 [7,8].

In conclusion, to the best of our knowledge, this is a rare case presented with bilateral deep vein thrombosis and pseudo paralysis. We think that the reporting of this case is important in drawing attention to the issue that COVID-19 plays a role in the involvement of vascular structures. For this reason, it should be kept in mind that COVID-19 patients may present with atypical symptoms in order to be diagnosed early.

## References

1. Lake MA. What we know so far: COVID-19 current clinical knowledge and research. *Clin Med (Lond)*. 2020;20(2):124-27.
2. Chen N, Zhou M, Dong X, Qu J, Gong F, Han Y, et al. Epidemiological and clinical characteristics of 99 cases of 2019 novel coronavirus pneumonia in Wuhan, China: A descriptive study. *Lancet*. 2020;395(10223):507-13.
3. Kavala AA, Türkyılmaz G, Satılmış OE, Akgül A. COVID-19' da koagülopati ve antikoagülasyon. Akgül A, editör. COVID-19 Vaskülopati, Post-COVID-19 Fenomeni ve Kalp Damar Cerrahisi. 1. Baskı. Ankara: Türkiye Klinikleri. 2020.43-6.
4. Zhoushan Health Commission. Additional instructions for a patient with 2019 nCoV. 2020.
5. Kim J, Thomsen T, Sell N, Goldsmith AJ. Abdominal and testicular pain: An atypical presentation of COVID-19. *Am J Emerg Med*. 2020;38(7):1542.
6. Alur İ, Ağladioğlu K, Güneş T, Taştan H, Tanrısever GY, Şenol H, et al. Postoperative venous thrombosis: frequency and risk factors in patients undergoing isolated coronary artery bypass graft surgery. *Damar Cer Derg* 2016;25(2):59-65.
7. Schmitt FCF, Manolov V, Morgenstern J, Fleming T, Heitmeier S, Uhle F, et al. Acute fibrinolysis shutdown occurs early in septic shock and is associated with increased morbidity and mortality: Results of an observational pilot study. *Ann Intensive Care*. 2019;9(1):19.
8. Cui S, Chen S, Li X, Liu S, Wang F. Prevalence of venous thromboembolism in patients with severe novel coronavirus pneumonia. *J Thromb Haemost*. 2020;18(6):1421-24.