

Acute Aortic Occlusion Due to Oral Contraceptive Use: Case Report

Oral Kontraseptif Kullanımına Bağlı Akut Aortik Oklüzyon: Olgu Sunumu

İhsan ALUR, MD,^a
Yusuf İzzettin ALİHANOĞLU, MD,^b
Gökhan ALTUNBAŞ, MD,^c
Bekir Serhat YILDIZ, MD,^d
Mehmet ÖZTÜRK, MD,^d
Emel ÖZKAN, MD^d

Clinics of

^aCardiovascular Surgery,

^cCardiology,

Denizli State Hospital,

^bDepartment of Cardiology,

Pamukkale University Faculty of Medicine,
Denizli

^cClinic of Cardiology,

Kilis State Hospital, Kilis

Geliş Tarihi/Received: 03.07.2012

Kabul Tarihi/Accepted: 25.09.2012

Yazışma Adresi/Correspondence:

İhsan ALUR, MD

Denizli State Hospital,

Clinic of Cardiovascular Surgery, Denizli,

TÜRKİYE/TURKEY

alur_i@hotmail.com

ABSTRACT Oral contraceptive drugs are known to cause hypercoagulability and induce arterial and venous thrombosis especially in patients with thrombophilias. Combined oral contraceptive pills increases the risk of venous thromboembolism by two times and arterial thromboemboli (myocardial infarction, ischemic stroke and peripheral emboli) risk by three times. Other risk factors for venous thromboembolism are increased age, obesity and thrombophilias. Thrombosis occurs as a result of interaction between hereditary and acquired risk factors. In this case, we report a 45 year-old female patient admitted to our clinic with sudden left leg pain in whom immediate multi slice computed tomography (MDCT) revealed acute aortic occlusion.

Key Words: Thromboembolism; contraceptive agents, female; aorta, abdominal

ÖZET Oral Kontraseptif ilaç kullanımı, özellikle trombofilisi olan bayanlarda sistemik hiperkoagülabileiteyi artırdığından dolayı arteriyel ve venöz tromboz riskini artırır. Kombine Oral Kontraseptif kullanımı Venöz Tromboemboli (VTE) riskini yaklaşık 2 kat, arteriyel tromboemboli (MI, iskemik strok, periferik hastalık) riskini yaklaşık 3 kat artırır. VTE riski; yaş, obezite ve trombofilisi ile artar. Tromboz, edinsel ve kalıtsal risk faktörlerinin interaktivasyonu sonucu oluşur. Bu yazıda ani başlayan sol bacak ağrısı nedeniyle çekilen çoklu kesitli Bilgisayarlı Tomografide Aort oklüzyonu tespit edilen 45 yaşında bayan hasta sunulmuştur.

Anahtar Kelimeler: Tromboembolizm; kontraseptif ajanlar, kadın; aort, abdominal

Damar Cer Derg 2012;21(3):255-8

Combined oral contraceptive (COC) pills, hormone replacement therapies (HRT) and pregnancy are known to induce a hypercoagulable state, especially in patients with thrombophilias, and may cause arterial and venous thrombosis. It is shown that COC use increases the risk of venous thromboembolism (VTE) by nearly two times and arterial thromboembolism risk (myocardial infarction, ischemic stroke and peripheral emboli) by almost three times.¹ There are some other risk factors known to increase the risk of VTE, the most frequent of these are obesity, increased age and thrombophilias. Risk factors for arterial thromboembolism are age, obesity, diabetes, smoking, hypertension and hyperlipidemia.

The combined oral contraceptive is not only highly effective, but it also has a remarkably good safety profile. Concerns over safety persist parti-

doi: 10.9739/uvcd.2012-31225

Copyright © 2012 by
Ulusal Vasküler Cerrahi Derneği

cularly with regard to venous thromboembolism (VTE), stroke and myocardial infarction (MI). Although epidemiological studies consistently show an increase in risk of VTE, the results are more controversial with regard to arterial diseases.²

CASE REPORT

A 45 year-old female patient admitted to our clinic with complaints of sudden severe left leg pain. Physical examination was remarkable for absent left posterior tibial and dorsalis pedis arterial pulses, whereas all other arterial pulses were palpable. Risk factors for thrombosis in the patient were oral contraceptive use (Gestoden; etinil estradiol) and smoking. Cardiac auscultation and electrocardiography were normal.

There was no flow in the left superficial femoral artery on arterial colored Doppler ultrasonography. Multi slice computed tomography (MDCT) taken after intravenous radiocontrast drug injection revealed near complete occlusion four centimeters long at the infrarenal portion of the abdominal aorta and filling defect compatible with thrombus (Figures 1 and 2). The patient underwent immediate surgery. Thrombectomy was performed using six French (6F) Fogarty catheter for aorta and five French (5F) Fogarty catheter for left superficial fe-

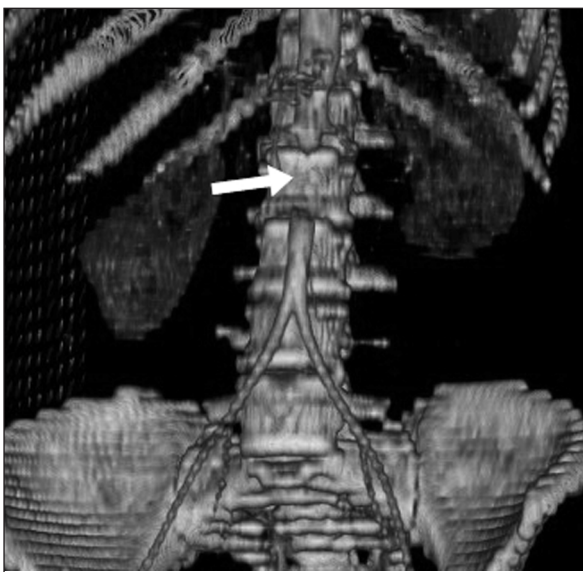


FIGURE 1: Aortic occlusion (white arrow).

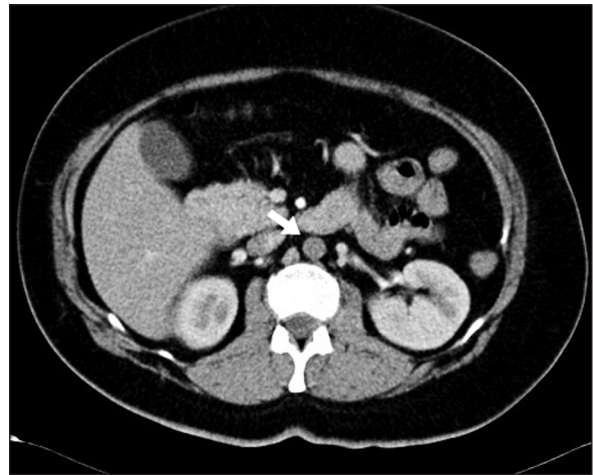


FIGURE 2: Transverse view (white arrow).

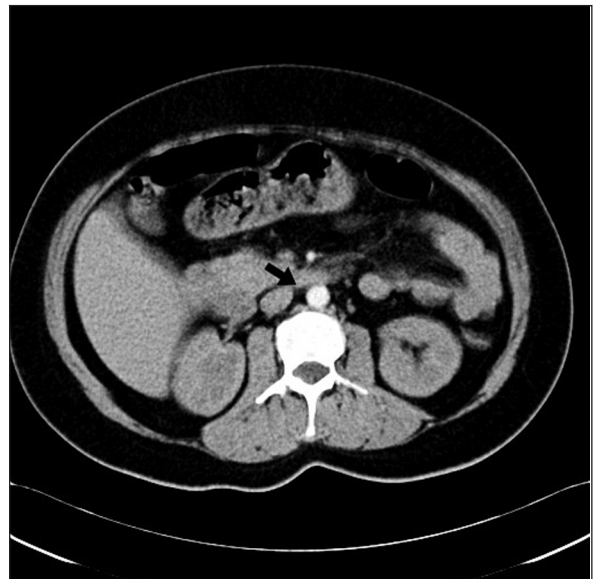


FIGURE 3: Patent aorta after embolectomy (black arrow).

moral artery (SFA) and fresh thrombus was discharged. Two hours after the operation, the patient complained of right leg pain. Right lower extremity pulses weren't palpable and again, emergent thrombectomy was performed and fresh thrombus was discharged from right SFA.

Postoperative period was uneventful, bilateral lower extremity pulses were palpable on physical examination and leg pain resolved completely. Aspirin and warfarin therapy started. Warfarin dosage was adjusted to achieve a target international

normalized ratio (INR) between 2.0 and 3.0. The patient was discharged on postoperative fifth day with complete recovery. On follow up, the patient was evaluated for hereditary thrombophilia but no anomaly was found. Control CT angiography was performed at second month (Figure 3).

DISCUSSION

There is published evidence showing interactions between oral contraceptives and cardiovascular and haemostatic system. Oral contraceptives induce both prothrombotic and fibrinolytic changes in haemostatic factors and an imbalance in haemostasis is likely to be important in oral contraceptive-induced VTE. The complexity of the changes involved and the difficulty of ascribing clinical significance has meant that uncertainty persists. A seriously under-researched area concerns vascular changes in oral contraceptive users.² Endothelial and myocardial estrogen receptors in cardiovascular system are responsible for rapid vasodilator response by the way of nitric oxide. In addition, they have inhibitory effects through genomic ways on the proliferation of smooth muscle cells and also increased endothelial cell growth in long-term.³

Histologically, endothelial and intimal proliferation have been identified in women exposed to high plasma estrogen concentrations and these lesions are associated with thrombotic occlusion. Other structural changes may result in increased vascular permeability, loss of vascular tone and venous stasis. With regard to arterial disease risk, epidemiological information relating to dose effects and joint effects with other risk factors, and studies of pathology and changes in risk factors, suggests that oral contraceptive use per se does not cause arterial disease.² It can, nevertheless, synergise very powerfully with subclinical endothelial damage to promote arterial occlusion. Accordingly, the prothrombotic effects of the oral contraceptive estrogen intervene in a cycle of endothelial damage and repair which would otherwise remain clinically silent or would ultimately progress - in, for example, the presence of cigarette smoking or hypertension- to atherosclerosis.

Numerous studies have found, with remarkable consistency, an elevated risk of venous thromboembolism among current users of low estrogen dose combined oral contraceptive (COC) drugs. The risk is substantially elevated among women with various inherited clotting factor defects. The effects in COC users with other risk factors for venous thrombosis tend to be less pronounced and more inconsistent. A number of studies have found higher relative risks among current users of low estrogen dose COCs containing desogestrel or gestodene, than among users of similar products containing levonorgestrel. The risk of cardiovascular disease of any description is low in COC users. Women can minimise, and possibly eliminate entirely, their arterial risks by not smoking and by having their blood pressure checked before using a COC (in order to avoid its use if raised blood pressure is discovered). Users may decrease their venous thromboembolic risk by their choice of COC preparation although the effects will be modest.⁴

The most frequent hereditary abnormalities in cases of thromboembolism are factor V Leiden (FVL, Arg506Gln) and prothrombin 20210G>A (FII 20210G>A) gene mutations.⁵ Even if a single heterozygote mutant gene is not protrombogenic per se, it can trigger thrombosis along with other hereditary defects or environmental predisposition. In other words, thrombosis occurs as a result of interaction between hereditary and acquired factors.

The frequency of factor V Leiden (FVL) mutation in thrombophilic patients is 40-60%. This hereditary abnormality is seen at a rate of 7% in European population and 4,6-7,1% in Turkey.^{6,7}

Some researchers investigated the role of these two variant genes (Factor V Leiden and prothrombin 20210G>A) in arterial thrombosis such as those in myocardial infarction.

However, despite the well known prothrombotic effects, association between factor V Leiden mutation and arterial thromboembolic events is still not clearly established.⁸

Our case was screened for hereditary thrombophilias but no anomaly was found, the only risk factor was oral contraceptive use. Warfarin was

prescribed and the patient was scheduled for outpatient follow up.

We thought that palpable pulsation of the right lower extremity was due to adequate arterial collateral circulation in spite of near complete occlusion of the abdominal aorta and that pulselessness of the left lower extremity was caused by thromboembolization from the abdominal aorta. On the other hand, we also thought that the right

femoral arterial embolization occurred at the second hour of the postoperative period was resulted from thrombectomy.

As a result, it should be considered that oral contraceptive drugs may lead to both arterial and venous serious thromboembolism in young female individuals and therefore the clinicians must be careful about these complications during the therapy.

REFERENCES

1. Bloemenkamp KMM, Helmerhorst FM. The oral contraceptive pill, mechanisms of vascular risk, and practical prescribing strategies for women with thrombotic problems. In: Greer IA, Ginsberg J, Forbes CD, eds. *Women's Vascular Health*. London: Arnold; 2007. p. 423-35.
2. Godsland IF, Winkler U, Lidegaard O, Crook D. Occlusive vascular diseases in oral contraceptive users. *Drugs* 2000;60(4): 721-869.
3. Mendelsohn ME, Karas RH. The protective effects of estrogen on the cardiovascular system. *N Engl J Med* 1999;340(23):1801-11.
4. Hannaford P. Cardiovascular events associated with different combined oral contraceptives: a review of current data. *Drug Saf*. 2000 May;22(5): 361- 71.
5. Oner F, Kaya A, Dogan R, Numanoglu N. Genetic risk factors of venous thromboembolism. *Tüberküloz Toraks* 2003;51(1):60-9.
6. İrdem A, Devecioğlu C, Batun S, Soker M, Sıcaklı İA. Prevalence of factor V Leiden and prothrombin G20210A ene mutation. *Saudi Med J* 2005;26(4):580-3.
7. Gurgey A, Mesci L. The prevalence of factor V Leiden 1691 G-->A) mutation in Turkey. *Turk J Pediatr* 1997;39(3):313-5.
8. Dönmez Y, Kanadasi M, Tanrıverdi K, Demir M, Demirtas M, Caylı M, et al. Prothrombin 20210GA and factor V Leiden mutations in patients less than 55 years old with myocardial infarction. *Jpn Heart J* 2004;45(3):505-12.