

Rapidly Occurring Carotid Artery Aneurysm in a Patient with Behcet Disease

Tevfik Güneş, Gökhan Önem, Hayati Taştan, and İhsan Alur, Denizli, Turkey

Behcet disease (BD) is a chronic systemic inflammatory disorder characterized by recurrent oral and genital ulcerations, uveitis, and skin lesions. Vascular system involvement is common in BD. Aneurysm formation appears to be more common than arterial occlusion. Extracranial carotid aneurysms in BD are extremely rare. In this report, we present rapidly expanding carotid pseudoaneurysm in a BD patient and its surgical treatment.

Behçet disease (BD) is a chronic systemic inflammatory disorder characterized by recurrent oral and genital ulcerations, uveitis, and skin lesions.¹ It primarily affects young adults. Vascular involvement is common, with venous thrombophlebitis being most frequent, followed by arterial aneurysms and occlusion.¹ Aneurysm formation is more common than arterial occlusion (65% vs. 35%). The arteries affected most commonly are the abdominal aorta and femoral and pulmonary arteries. Extracranial carotid aneurysms are very rare in BD.^{2,3} This report presents a rapidly expanding carotid pseudoaneurysm in a BD patient and its surgical treatment.

a pulsating mass in the right anterior cervical region (Fig. 1). The neurologic examination was normal. Blood tests showed an erythrocyte sedimentation rate of 39 mm/hr, and a C-reactive protein level of 3.06 mg/dL

CASE REPORT

A 37-year-old man was admitted for a right-sided cervical mass present for 2 weeks. He had a 14-year history of BD. There was no history of trauma, surgery, or irradiation to his neck. He had a history of recurrent oral and genital aphthous lesions, uveitis, and maculopapular rashes on his lower extremities. The physical examination revealed

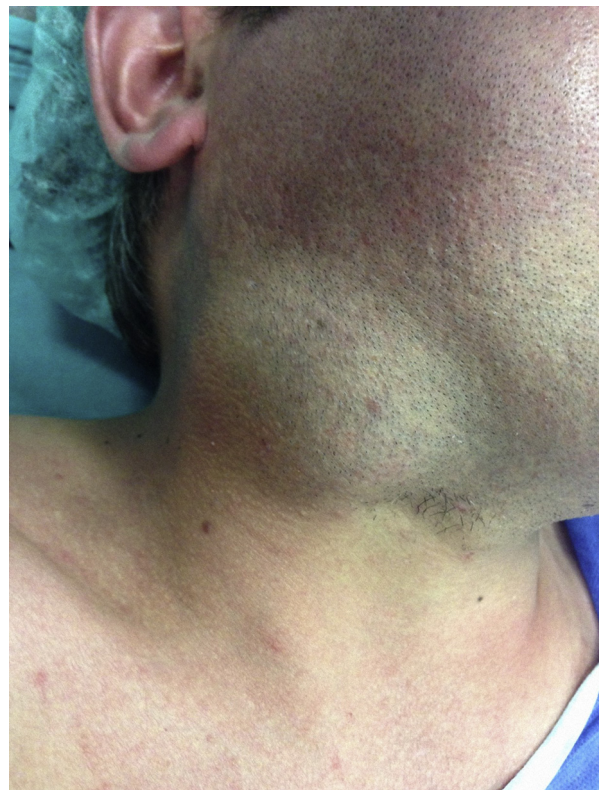

Fig. 1. The rapidly expanding pulsatile mass on the right side of the neck.

Department of Cardiovascular Surgery, Faculty of Medicine, Pamukkale University, Denizli, Turkey.

Correspondence to: Tevfik Güneş, MD, Department of Cardiovascular Surgery, Faculty of Medicine, Pamukkale University, Kınıklı, Denizli 20070, Turkey; E-mail: tevfik04@yahoo.com

Ann Vasc Surg 2015; 29: 836.e5–836.e8
<http://dx.doi.org/10.1016/j.avsg.2014.10.033>

© 2015 Elsevier Inc. All rights reserved.

Manuscript received: July 27, 2014; manuscript accepted: October 24, 2014; published online: February 11, 2015.

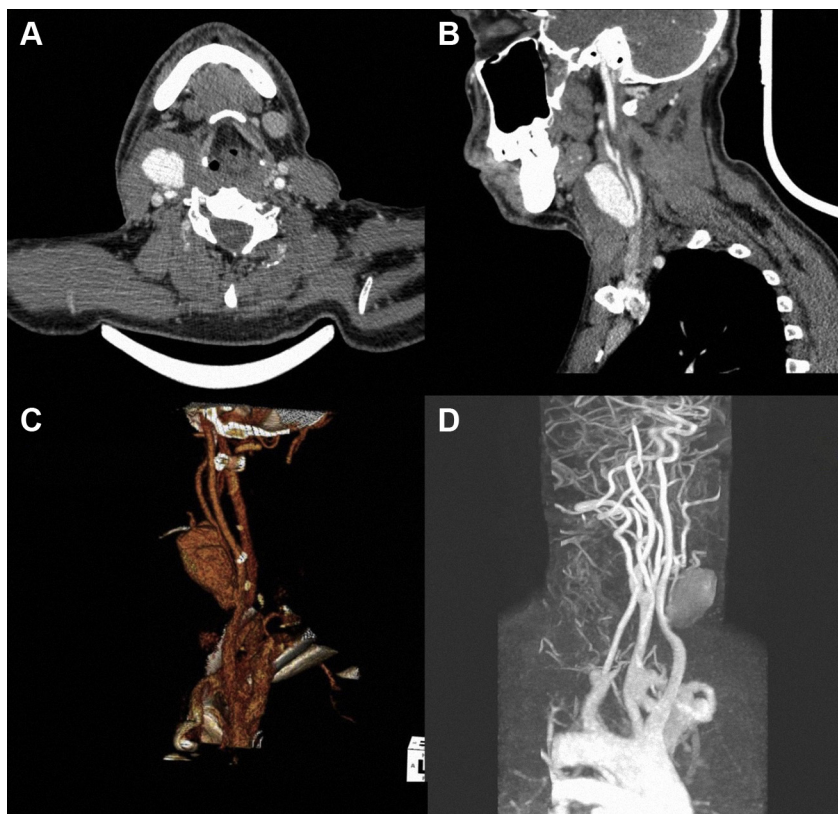


Fig. 2. (A) Carotid pseudoaneurysm was demonstrated with computed tomography. (B) Sagittal view of pseudoaneurysm in computed tomography. (C) Three-dimensional computed tomographic view

of the right carotid artery pseudoaneurysm. (D) MR angiography shows the pseudoaneurysm of the right common carotid artery.

(normal 0.5 mg/dL). Ultrasonography revealed a pseudoaneurysm of the right common carotid artery (CCA); the aneurysm arose from the CCA bifurcation, and the external carotid artery originated from the proximal portion of the aneurysm. Computed tomography and magnetic resonance imagining (MRI) angiography revealed a 5-cm pseudoaneurysm containing a thrombus at the right carotid artery bifurcation. The right external carotid artery arose from the aneurysm sac (Fig. 2). The patient was referred to rheumatology for medication. Early surgery was performed to prevent fatal complications of this rapidly expanding pseudoaneurysm.

Under general anesthesia and endotracheal intubation, the patient was positioned for a carotid endarterectomy. First, the saphenous vein was prepared from the proximal part of the right lower extremity. Second, an incision was made in the neck along the anterior border of the sternocleidomastoid muscle. The pseudoaneurysm was adherent to the sternocleidomastoid muscle. Before exploring the pseudoaneurysm, we explored the right CCA and prepared it for clamping. Isolation and external clamping of the internal or external carotid artery distal to the pseudoaneurysm were impossible. After administering heparin, the CCA was clamped. The

pseudoaneurysm sac was opened, and a mural thrombus was removed. The external carotid artery was explored and clamped easily. However, because of the excessive backflow from the internal carotid artery and adherence, the internal carotid artery could not be explored or clamped. Therefore, we occluded it by compression and then established a carotid shunt (Fig. 3A, B). Then stump pressure (SP) was measured (SP, 60 mm Hg). Reconstruction was performed via both interposition and patch using a piece of the saphenous vein graft. The proximal part of the saphenous vein was used as a patch to repair the gap between the internal carotid artery and CCAs, and the distal part was sutured to the external carotid artery orifice (Fig. 3C). There were no postoperative complications. The patient was discharged on the sixth postoperative day on 20 mg/day prednisolone and 300 mg/day acetyl salicylic acid. Four months postoperatively, he is symptom-free, and Doppler ultrasonography and MRI angiography (Fig. 4) documented the patency of the graft and patch. The histologic examination of the false aneurysm wall showed foci of inflammatory exudation with lymphocytes, mononuclear cells, and neutrophils and the absence of an internal and external elastic membrane.

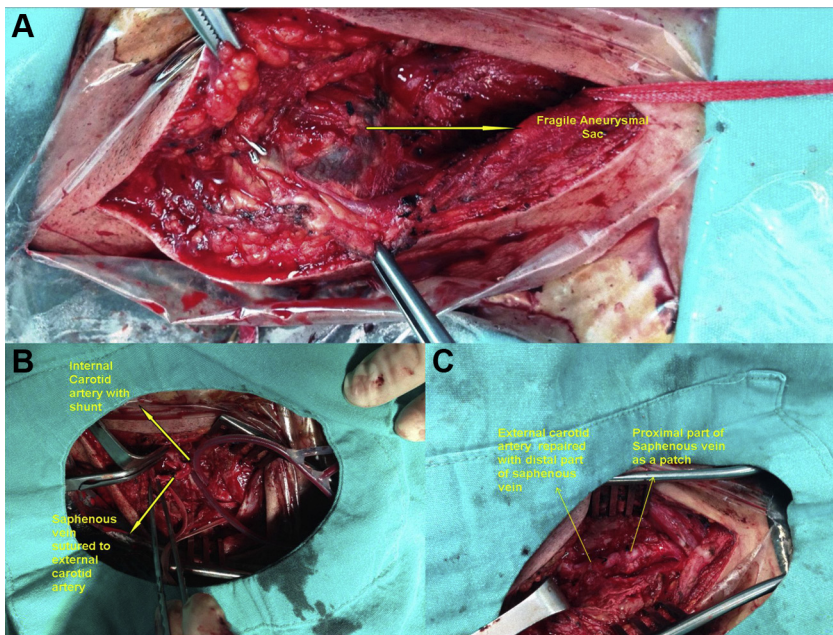


Fig. 3. (A) The fragile pseudoaneurysmal sac. (B) Carotid shunt was established between common and internal carotid artery. (C) Intraoperative image after procedure.




Fig. 4. The view of postoperative MRI angiography.

DISCUSSION

BD is a multisystem disorder of unknown etiology that is seen mostly in Mediterranean countries, the Middle East, and Eastern Asia. It is now recognized as a chronic recurrent inflammatory syndrome secondary to small-vessel vasculitis.^{4,5}

Vascular system involvement is common in BD, with a prevalence of 7–29% and has a serious effect on the course of the disease.^{4,5} Vascular lesions are most likely to involve the venous system; however, arterial involvement is more problematic. Arterial lesions occur in 3–5% of patients, often in the form of a rapidly expanding aneurysm. The pathogenesis of the aneurysmal degeneration is thought

to be vasculitis resulting in obliterative endarteritis of the vasa vasorum supplying medium-sized and large vessels.^{4,6} The reported interval between the onset of BD and that of arterial involvement is 5–9 years,⁷ although our patient had a 14-year history of BD.

Once vascular disease develops, the progression to aneurysm formation can be rapid.⁴ The most common site of aneurysm formation is the abdominal aorta, followed by the femoral and pulmonary arteries. Extracranial carotid artery aneurysms are uncommon. Surgery is usually recommended for managing arterial aneurysms because their rupture is the primary cause of death in patients with BD.^{5,6}

To prevent complications in active disease, endovascular intervention is a reasonable alternative.⁵ It is preferred in patients who are suitable anatomically. We did not consider endovascular therapy to be appropriate because the right external carotid artery arose from the aneurysm sac, and coil embolization could not be performed. Ligation of the diseased arteries is another treatment choice in appropriate cases because of the high incidence of graft occlusion.^{3,6}

Owing to the fragility of the involved arteries, patients with vascular Behçet syndrome undergoing surgery are at high risk of late postoperative complications, such as a pseudoaneurysm at the anastomotic site, with a frequency of 30–50%. To prevent this complication, the graft should be anastomosed to a healthy artery.⁶ We chose to restore the cerebral circulation using a saphenous vein graft in this young patient and found healthy tissue for reconstruction. Berard et al. stated that they preferred synthetic material because of the belief that vasculitis might be present in venous tissue, and avoiding the use of autologous grafts might decrease the long-term risk of complications. On the other hand, Koksoy et al. reported that using polytetrafluorethylene or saphenous vein grafts did not influence the outcome in terms of the complication rate.^{2,7,8} The choice of graft is still controversial.

Medical treatment for BD is important for managing vascular manifestations. The European League Against Rheumatism recommendations suggest that immunosuppressants lower the recurrence risk and propose cyclophosphamide and corticosteroids for managing peripheral arterial aneurysms. In addition, preoperative immunosuppression should be initiated immediately, but postponing the intervention is not always feasible, particularly in symptomatic aneurysms.^{2,3,9}

In conclusion, patients with BD should be evaluated regularly to diagnose arterial complications early. Extracranial carotid aneurysms are extremely rare in these patients. However, the time to aneurysm expansion is shorter in patients with BD, and they potentially are at a high risk of rupture. Consequently, an aggressive therapeutic approach seems appropriate. In addition, endovascular therapy might be an alternative for surgically inaccessible aneurysms.

REFERENCES

1. Alpagut U, Ugurlucan M, Daytuglu E. Major arterial involvement and review of Behçet's disease. *Ann Vasc Surg* 2007;21:232–9.
2. Berard X, Corpataux JM, Taoufiq H, et al. Don't trust a vein graft to treat carotid aneurysm in patients with Behçet disease. *J Vasc Surg* 2010;52:471–4.
3. Sayed A, Elwan H, Fouad F, et al. Behçet extracranial carotid aneurysms: is there still a role for ligation? *Eur J Vasc Endovasc Surg* 2010;39:17–22.
4. Kuzu MA, Ozaslan C, Koksoy C, et al. Vascular involvement in Behçet's disease: 8-year audit. *World J Surg* 1994;18:948–53.
5. Ohshima T, Miyachi S, Hattori K, et al. A case of giant common carotid artery aneurysm associated with vascular Behçet disease: successfully treated with a covered stent. *Surg Neurol* 2008;69:297–301.
6. Bouarhroum A, Sedki N, Bouziane Z, et al. Extracranial carotid aneurysm in Behçet disease: report of two new cases. *J Vasc Surg* 2006;43:627–30.
7. Koksoy C, Gyedu A, Alacayir I, et al. Surgical treatment of peripheral aneurysms in patients with Behçet's disease. *Eur J Vasc Endovasc Surg* 2011;42:525–30.
8. Kalko Y, Basaran M, Aydin U, et al. The surgical treatment of arterial aneurysms in Behçet disease: a report of 16 patients. *J Vasc Surg* 2005;42:673–7.
9. Hatemi G, Silman A, Bang D, et al. EULAR recommendations for the management of Behçet disease. *Ann Rheum Dis* 2008;67:1656–62.